

Case Series: Three Patients With Lower Extremity Ulcerations Treated With V.A.C.® GranuFoam® Silver™ Dressing

THE V.A.C.® VACUUM ASSISTED CLOSURE™ System Clinical Results

CASE STUDY 1:

Patient:

Fifty-four-year-old caucasian female with a medical history of rheumatoid arthritis (RA) for 14 years, steroid therapy for 13 years, and smoking. Surgical history includes removal of a rheumatoid nodule 3 years prior to this presentation. Since that time the patient has developed a chronic non-healing right ulcer over the malleolus that has a known history of osteomyelitis and currently cultures positive for Methicillin-resistant *Staphylococcus aureus* (Figure 1, A).

Diagnosis:

At the time of admission the wound assessment revealed osteomyelitis in the right lateral malleolus with ulceration probing to bone. A deep tissue culture performed just prior to initial wound treatment returned positive for *Peptostreptococcus asaccharolyticus*.

Initial Wound Treatment:

On day 1 of treatment the patient was taken to the OR for debridement of a large portion of the lateral malleolus (Figure 1, B) and subsequent placement of Vancomycin-impregnated polymethylmethacrylate beads to treat the osteomyelitis. Following this procedure the patient was discharged home on IV antimicrobial therapy with plans to continue the wound care as an outpatient.

V.A.C.® Therapy System™ Initiation:

One week later, the wound culture returned negative for infection and the antibiotic beads were removed. The treatment goal for this patient was two-fold—to reduce the potential for recurrent deep tissue infection^{1,3} and to stimulate granulation tissue formation^{4,5} in preparation for surgical closure.⁶⁻⁸ To accomplish this goal the treating physicians chose to use V.A.C.® Therapy System™ with V.A.C.® GranuFoam® Silver™ Dressing and the Papineau technique. The Papineau technique of packing cancellous bone chips into the granulation for fibula reconstitution was applied concomitant with V.A.C.® Therapy System™ and V.A.C.® GranuFoam® Silver™ Dressing at 125 mmHg of continuous negative pressure.²

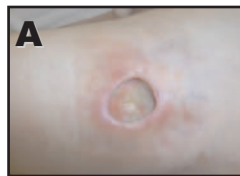Wound Progress (See Figure 1 and Table 2):

V.A.C.® Therapy was applied for 43 days using the V.A.C.® GranuFoam® Silver™ Dressing. At 1 week, the wound was considerably contracted (Figure 1, C). On day 21 of therapy, the wound was approximately 50% granulated, with approximately 50% incorporation of the Papineau bone graft. On therapy day 30 (Figure 1, D) the wound was surgically debrided and a rotational extensor digitorum brevis (EDB) muscle flap was performed (Figure 1, E)⁹ followed by a split-thickness skin graft to secure the flap (Figure 1, F). V.A.C.® Therapy was re-initiated at 125 mmHg of continuous negative pressure over the graft with a non-adherent layer dressing placed between the graft and the V.A.C.® GranuFoam® Silver™ Dressing¹⁰ (Figure 1, G). The patient continued V.A.C.® Therapy, with regular dressing changes, for 13 more days post flap and graft.

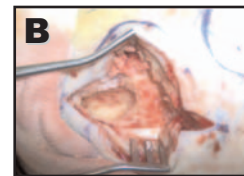
Patient Discharge and Follow-up:

V.A.C.® Therapy with V.A.C.® GranuFoam® Silver™ Dressing was discontinued on day 43, along with the systemic antibiotics. Figure 1, H shows the re-epithelializing wound at 1 week post discontinuation. Against medical advice, the patient began smoking after the flap procedure, which stalled healing and contributed to partial necrosis of the flap and graft. Follow-up care included wet-to-moist gauze, a walking cast and wound debridements. To help stimulate healing, V.A.C.® Therapy was re-initiated for 19 days with traditional GranuFoam® Dressings 1 month after discontinuing therapy with the V.A.C.® GranuFoam® Silver™ Dressing. Following traditional V.A.C.® Therapy, the wound was treated with wet-to-moist gauze until closure. Figure 1, I shows the wound at the 3 month follow-up post treatment with the V.A.C.® Therapy System™.

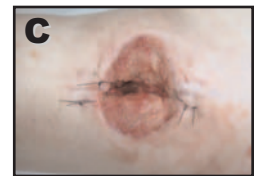
Figure 1



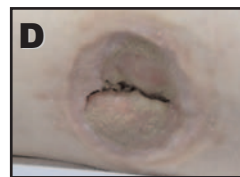Ulcer at initial presentation



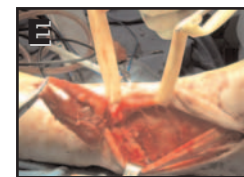Initial OR debridement showing medullary canal of fibula and extensive debridement



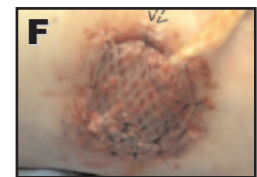
Day 7 of V.A.C.® Therapy with V.A.C.® GranuFoam® Silver™ Dressing



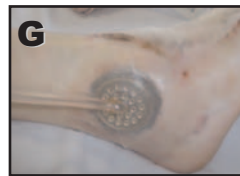Day 30 of V.A.C.® Therapy with V.A.C.® GranuFoam® Silver™ Dressing



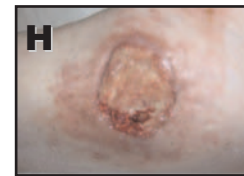
Day 30 EDB Muscle Flap performed



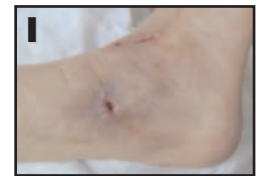Day 30 STSG placed post EDB muscle flap



V.A.C.® GranuFoam® Silver™ Dressing applied intra-operatively after STSG and EDB muscle flap



1 week post discontinuation of V.A.C.® Therapy with GranuFoam® Silver™ Dressing



3 month follow-up post V.A.C.® Therapy with GranuFoam® Silver™ Dressing

Clinical Outcomes:

This chronic ulcer had been present for 3 years prior to this presentation. None of the advanced wound care treatments attempted during this 3 year period were able to close the wound, including surgical debridements and HBO. The combination of antibiotic therapy to treat the osteomyelitis and V.A.C.[®] Therapy with V.A.C.[®] GranuFoam[®] Silver™ Dressing helped create a controlled wound environment that facilitated closure of this chronic ulcer which had been open for 3 years. No odor or signs of infection were present throughout the entire length of therapy. In the physicians' opinion the use V.A.C.[®] Therapy with V.A.C.[®] GranuFoam[®] Silver™ Dressing was a better choice over additional HBO treatments to promote granulation tissue coverage over the exposed underlying structures. Although the re-epithelialization process was slowed by the patient's re-initiation of smoking, the wound remained fully granulated for the long-term. In the opinion of the physicians, the effective bone coverage and subsequent closure, led to a reduced treatment time and a decreased duration of outpatient antibiotic therapy, thus, avoiding a BKA and all related expenses.

CASE STUDY 2:

Patient:

Sixty-four-year-old caucasian female with a 25-year history of Type II Diabetes Mellitus, morbid obesity, hypertension, left-foot Charcot neuro-arthropathy, and bilateral peripheral neuropathy. Recent history of a gallbladder tumor treated with chemotherapy and radiation 6 months prior to this presentation.

Diagnosis:

Chronic medial ulceration of the right first metatarsalphalangeal joint with osteomyelitis of exposed head of right first metatarsal and base of proximal phalanx (Figure 2, A). Purulent drainage was visually expressible and a wound culture returned positive for *Enterococcus*.

Initial Wound Treatment:

Prior to admission, this wound had been open for 4 months and was treated with daily gentian violet with a dry sterile dressing at another institution. No antibiotic therapy or bone biopsy was on record. A pre-operative x-ray of the right foot showed cortical destruction of the distal right first metatarsal and base of proximal phalanx of the right hallux.

Upon admission the wound underwent surgical debridement via resection of the right first metatarsal head and base of proximal phalanx of the hallux. Arthrodiastasis was achieved with a mini-external fixator to allow for soft tissue granulation in the area of resected bone (Figure 2, B). Antibiotic therapy was initiated.

V.A.C.[®] Therapy System™ Initiation:

One day after application of the mini-external fixator, V.A.C.[®] Therapy with V.A.C.[®] GranuFoam[®] Silver™ Dressing was initiated at 125 mmHg of continuous negative pressure (Figure 2, C). The goal of therapy for this patient was to prepare the wound for a split-thickness skin graft by helping to reduce infection^{11,12} and assisting granulation tissue formation over exposed structures.^{5,13} The patient was assigned to a wheelchair for off-loading, and was discharged 2 days later on the V.A.C.[®] Therapy System™.

Wound Progress (See Figure 2 and Table 2):

V.A.C.[®] Therapy with the V.A.C.[®] GranuFoam[®] Silver™ Dressing was applied to the wound for 46 days. The wound was clear of visible signs of infection on therapy day 3. However, the physicians chose to continue with the V.A.C.[®] GranuFoam[®] Silver™ Dressing to avoid the wound being re-infected throughout the length of therapy.^{3,12} On day 19, all structures were covered with granulation tissue (Figure 2, D). After 41 days of therapy, the wound bed was prepared for a split-thickness skin graft (STSG), which was applied medially to the right first metatarsalphalangeal joint region (Figure 2, E). The STSG was covered with a non-adherent layer and V.A.C.[®] Therapy with the V.A.C.[®] GranuFoam[®] Silver™ Dressing was applied at 75 mmHg of continuous negative pressure for 5 days.¹⁰

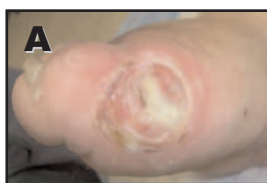Patient Discharge and Follow-up:

Sufficient graft take was achieved with the STSG. The residual wound was debrided weekly and treated with a fenestrated silicone dressing with implantation of a bi-layered living skin equivalent 3 weeks post discontinuation of the V.A.C.[®] Therapy System™. The wound progressed to full epithelialization 10 weeks later (Figure 2, F).

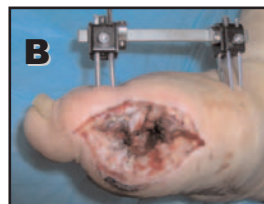
Clinical Outcomes:

In the physicians' opinion, the combination of V.A.C.[®] Therapy with the V.A.C.[®] GranuFoam[®] Silver™ Dressing and antibiotic therapy provided antimicrobial protection for the clean residual bone ends and avoidance of recurrent osteomyelitis until granulation tissue coverage could be obtained. The granulation tissue coverage and subsequent grafting helped to successfully avoid a first toe and metatarsal amputation.

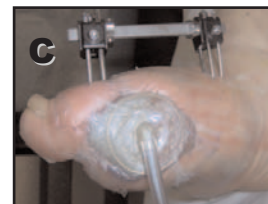
Figure 2



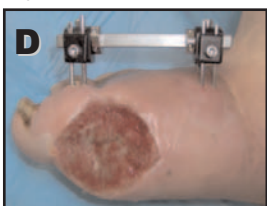
Wound at admission with purulent drainage visually expressible



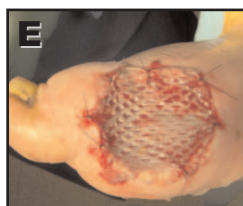Wound post resection of distal first metatarsal and base of proximal phalanx



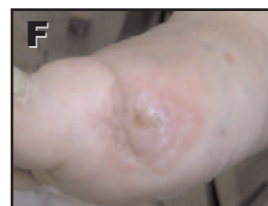V.A.C.[®] Therapy initiated post-operatively with V.A.C.[®] GranuFoam[®] Silver™ Dressings



Day 19 of V.A.C.[®] Therapy with V.A.C.[®] GranuFoam[®] Silver™ Dressings



Wound granulated to surface on day 41 of V.A.C.[®] Therapy; STSG placed



3 month follow-up post discontinuation of the V.A.C.[®] Therapy System™

CASE STUDY 3:

Patient:

Sixty-four-year-old hispanic male with a history of poorly controlled Type II Diabetes Mellitus, hypertension, peripheral vascular disease, peripheral neuropathy, and currently on steroid therapy. Patient was admitted for right lower extremity cellulitis with an infected ulceration of sub-metatarsal five with suspected osteomyelitis. The ulcer had developed 4 weeks prior and despite the patient being instructed on wound care it had worsened over time. Three days prior to this hospital admission he developed a fever, chills, pain, swelling and loss of right leg function.

Diagnosis:

Examination revealed ulceration of the right submetatarsal five and probing to the fifth metatarsal head plantarly. The ulceration measured 4.0 x 4.0 cm with a necrotic wound bed and foul odor. Undermining and tunneling were present. A wound culture returned positive for beta hemolytic *Streptococcus* group B, *Enterococcus faecalis*, *Enterobacter cloacae*, and *Pseudomonas aeruginosa*. The patient was confirmed to have both a progressive infection and osteomyelitis.

Initial Wound Treatment:

Upon admission, an immediate bedside incision and drainage was performed and antibiotic therapy was administered to treat the acute infection and osteomyelitis. The following day, a partial fifth ray resection and radical wound debridement were performed. Intra-operative findings were consistent with *Streptococcus* infection including liquefaction of the subcutaneous tissue and thrombosis of vessels.

The dorsal ankle and foot were debrided and irrigated (Figure 3, A). V.A.C.[®] Therapy with a traditional GranuFoam[®] Dressing was initiated on the surgical wound for 6 days. Debridement and irrigation were performed at each dressing change. On day 7, a split-thickness skin graft (STSG) was placed (Figure 3, B) and V.A.C.[®] Therapy was initiated over the STSG with a non-adherent layer dressing in-between. On day 11, V.A.C.[®] Therapy was discontinued and patient was discharged home on antibiotic therapy.

Approximately 35% loss of the initial STSG was noted at the first outpatient follow-up visit, 3 days post-discharge. The residual wound area measured 13.5 x 10.0 x 0.5 cm with exposed bone and tendon. Local wound care was performed with excision debridement and collagenase dressings weekly, with little progress towards closure (Figure 3, C). One month following patient discharge, V.A.C.[®] Therapy was re-initiated with the V.A.C.[®] GranuFoam[®] Silver[™] Dressing.

V.A.C.[®] Therapy System[™] Initiation:

V.A.C.[®] Therapy was initiated over the residual wound at 125 mmHg continuous negative pressure. All dressing changes were performed in an outpatient setting. The wound measured 12.5 x 8.0 x 0.5 cm and again cultured positive for osteomyelitis. Systemic antibiotics were administered to treat the osteomyelitis. The goal of therapy for this patient was to help reduce the infection that was suspected to have caused partial skin graft failure^{11,12} and to help reduce the infection in preparation for a cultured skin graft of the areas that the STSG did not incorporate.^{14,15}

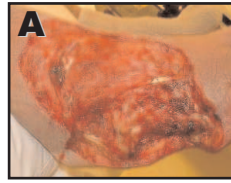Wound Progress (See Figure 3 and Table 2):

V.A.C.[®] Therapy was applied for 8 weeks using the V.A.C.[®] GranuFoam[®] Silver[™] Dressing. The wound began to contract and granulate in with the combination of V.A.C.[®] Therapy and the V.A.C.[®] GranuFoam[®] Silver[™] Dressing and weekly debridements at the wound center. At 1 week, the wound was free of visible signs of infection and odor. Due to the patient's history of chronic infection, the physicians chose to continue with the V.A.C.[®] GranuFoam[®] Silver[™] Dressing through the length of therapy to help protect against recurrent infection.^{11,12} At 3 weeks, the wound measured 8.0 x 7.5 x 0.2 cm (Figure 3, D). At 5 weeks, a wound tissue culture showed light growth of *pseudomonas aeruginosa* and *enterobacter cloacae* and the antibiotic was adjusted to treat these bacteria. At 7 weeks (Figure 3, E) a third bone debridement occurred, and at 8 weeks, adequate granulation coverage of the bone and peroneal tendon were noted. At this time, a cultured skin graft and meshed bilayered cultured graft were placed on the residual wound and V.A.C.[®] Therapy was discontinued.

Patient Discharge and Follow-up:

One week following discontinuation of V.A.C.[®] Therapy, the graft was evaluated and noted to be incorporating well with active contracture of the wound. Continued wound contracture occurred with local wound care, and a final bone biopsy 10 weeks post-discontinuation of V.A.C.[®] Therapy revealed healthy bone adjacent to the residual defect. An x-ray showed massive dissolution of bone consistent with Charcot neuroarthropathy, which occurred after emergent surgery in this neuropathic limb. Therefore, the foot was placed in an air cast until consolidation of the soft bone could be achieved. Figure 3, F shows a closed wound at 3 months post-discontinuation of treatment with the V.A.C.[®] Therapy System[™], at which time the patient remained asymptomatic with a plantigrade foot.

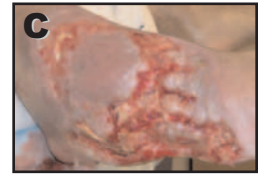Figure 3



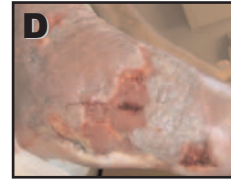Wound post-debridement of infected tissue



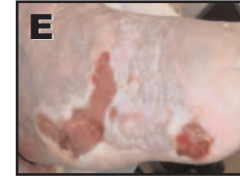STSG placed on day 7



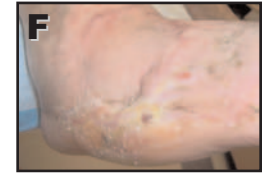Graft necrosis 3 weeks post discharge home



After 3 weeks of V.A.C.[®] Therapy with GranuFoam[®] Silver[™] Dressing



After 7 weeks of V.A.C.[®] Therapy with GranuFoam[®] Silver[™] Dressing



At 3 month follow-up post V.A.C.[®] Therapy with GranuFoam[®] Silver[™] Dressing

Clinical Outcome:

In the physicians' opinion, the combination of V.A.C.[®] Therapy with the V.A.C.[®] GranuFoam[®] Silver™ Dressing helped reduce deep tissue infection in this chronic wound. The post-graft residual wound had been treated with advanced wound care for 1 month with no change in wound depth, and bone and tendon remained exposed during this time. After 3 weeks of V.A.C.[®] Therapy with the V.A.C.[®] GranuFoam[®] Silver™ Dressing, the wound depth was reduced by more than 50%. Antibiotic therapy and bone debridements were effective in treating the osteomyelitis, and the physicians believe that V.A.C.[®] Therapy and the V.A.C.[®] GranuFoam[®] Silver™ Dressing were instrumental in helping reduce infection and assisting granulation tissue growth over the exposed structures. Due to the patient's comorbidities and history of infection, efficient closure of this wound was critical in preventing further deterioration of tissue and bone which could potentially result in amputation.

Case Series References:

Brent Bernstein, DPM, FACFAS, Director of Charcot and Reconstructive Foot Program; Todd Bolokowski, DPM; Bryan A. Blanck, DPM; Jung Lee, DPM; St. Luke's Hospital and Health Network, Pennsylvania, USA

Table 1. Data for Three Patients With Lower Extremity Ulcerations Treated With V.A.C.[®] GranuFoam[®] Silver™ Dressing

Pat ID #	Age (yr)	M / F	Pre-existing Condition	Diagnosis	Time wound open/infected before V.A.C. [®] placement	Therapies attempted prior to V.A.C. [®] Therapy (if applicable)	Wound area post debridement at V.A.C. [®] placement (cm ²)	Wound depth post debridement at V.A.C. [®] placement (cm ³)
1	54	F	RA, osteomyelitis	Right lateral malleolus with ulceration probing to bone	3 yrs/3 yrs	Surgical debridements, HBO, IV antibiotic therapy, casts, traditional V.A.C. [®] Therapy, silver sulfa-diazine cream, growth factor gel, collagen dressings, gauze, topical antibiotic ointment	12 cm ²	1.5 cm ³
2	64	F	Type II DM, morbid obesity, HTN, Charcot neuroarthropathy, peripheral neuropathy, gallbladder tumor	Chronic ulcer with osteomyelitis and exposed metatarsal and phalanx	4 months/4 months	Gentian violet with dry sterile dressing	22 cm ²	2.0 cm ³
3	64	M	Type II DM, HTN, PVD, peripheral neuropathy, cellulitis	Progressive acute infection, osteomyelitis	4 weeks/4 weeks	Wet-to-dry gauze	135 cm ²	0.5 cm ³

* Clinical data in table referenced from St. Luke's Hospital and Health Network (Pennsylvania, USA) facility medical records, 2005-6.

Table 2. Data for Three Patients With Lower Extremity Ulcerations Treated With V.A.C.[®] GranuFoam[®] Silver™ Dressing

Pat ID #	Organisms present on initial culture	# of days V.A.C. [®] Therapy w/ GranuFoam [®] Silver™ Dressing used	Wound clear of clinical infection (day X)	Time to wound closure	Method of wound closure	Days to patient discharge (post-V.A.C. [®] Therapy initiation)
1	<i>Peptostreptococcus asaccharolyticus</i>	43	0	4.5 months	EDB muscle flap and skin graft	All outpatient
2	<i>Streptococcus, Enterococcus, MRSA</i>	46	3	41 days	STSG, Cultured skin graft	2
3	<i>Pseudomonas aeruginosa, Enterococcus, Enterobacter cloacae</i>	55	7	4.5 months	STSG, Cultured skin graft	All outpatient

* Clinical data in table referenced from St. Luke's Hospital and Health Network (Pennsylvania, USA) facility medical records, 2005-6.

REFERENCES:

- Burrell RE, Heggers JP, Davis GJ, Wright JB. Efficacy of silver-coated dressings as bacterial barriers in rodent burn sepsis model. *Wounds*, 1999; 11(4): 64-71.
- Papineau LJ, Alfageme A, Dalcourt JP, Pilon L. [Chronic osteomyelitis: open excision and grafting after saucerization (author's transl)]. *International Orthopaedics*, 1979; 3(3): 165-76.
- Warriner R, Burrell R. Infection and the chronic wound: A focus on silver. *Advances in Skin & Wound Care*, 2005; 18(Suppl 1): 2-12.
- Joseph E, Hamori CA, Bergman S, Roaf E, Swann N, Anastasi G. Prospective randomized trial of vacuum-assisted closure versus standard therapy of chronic non-healing wounds. *Wounds*, 2000; 12(3): 60-67.
- DeFranzo AJ, Argenta LC, Marks MW, Molnar JA, David LR, Webb LX, Ward WG, Teasdall RG. The use of vacuum-assisted closure therapy for the treatment of lower-extremity wounds with exposed bone. *Plastic & Reconstructive Surgery*, 2001; 108(5): 1184-91.
- Argenta LC, Morykwas MJ. Vacuum-assisted closure: A new method for wound control and treatment: Clinical experience. *Annals of Plastic Surgery*, 1997; 38(6): 563-77.
- Scholl L, Chang E, Reitz B, Chang J. Sternal osteomyelitis. *J Card Surgery*, 2004; 5(19): 453-61.
- Horch RE, Kopp J, Bach AD, Kneser U. Pre-treatment of pressure ulcers using subatmospheric pressure dressings enhances plastic surgical coverage. Presented at EPUAP Panel meeting, Aberdeen, Scotland, May 5-7 2005.
- McHenry TP, Early JS, Schacherer TG. Peroneus Brevis Rotation Flap: Anatomic Considerations and Clinical Experience. *Journal of Trauma-Injury Infection & Critical Care*, 2001; 50(5): 922-926.
- Holder IA, Durkee P, Supp AP, Boyce ST. Assessment of a silver-coated barrier dressing for potential use with skin grafts on excised burns. *Burns*, 2003; 29: 445-448.
- White RJ. An Historical overview of the use of silver in wound management. *Br. J. Nurs.*, 2001; 10: S3-8.
- Demling RH, DiSanti L. The role of silver technology in wound healing: Effects of silver on wound management. *Wounds*, 2001; 13(5): 15-21
- Kopp J, Kneser U, Bach AD, and Horch RE. Buried chip skin grafting in neuropathic diabetic foot ulcers following vacuum-assisted wound bed preparation: enhancing a classic surgical tool with novel technologies. *Int J Low Extrem Wounds*, 2004; 3: 168-71.
- Meara JG, Guo L, Smith JD, Pribaz JJ, Breuing KH, Orgill DP. Vacuum Assisted Closure in the treatment of degloving injuries. *Annals of Plastic Surgery*, 1999; 42(6): 589-94.
- Armstrong DG, Lavery LA, Abu-Rumman P, et al. Outcomes of subatmospheric pressure dressing therapy on wounds of the diabetic foot. *Ost Wound Mgmt*, 2002; 48(4): 64-68.
- Data estimates based on St. Luke's Hospital and Health Network records, Pennsylvania, USA, 2005-6.



NOTE: As with any case study, the results and outcomes should not be interpreted as a guarantee or warranty of similar results. Individual results may vary depending on the patient's circumstances and condition. Clinical Outcomes and benefits of V.A.C.[®] Therapy reported are based on data and observational experience of the reporting facility and case physician.

NOTE: Specific indications, contraindications, warnings, and precautions exist for this product and therapy. Please consult a physician, product instructions, and recommended guidelines prior to application. Rx only.

©2006 KCI Licensing, Inc. All rights reserved. 8023 Vantage Drive, San Antonio, TX 78230.

Unless otherwise indicated, trademarks and services marks herein are the property of KCI, its affiliates, and licensors. The V.A.C.[®] System™ is subject to patents and/or pending patents. Rev. 4/2006 29-D-280